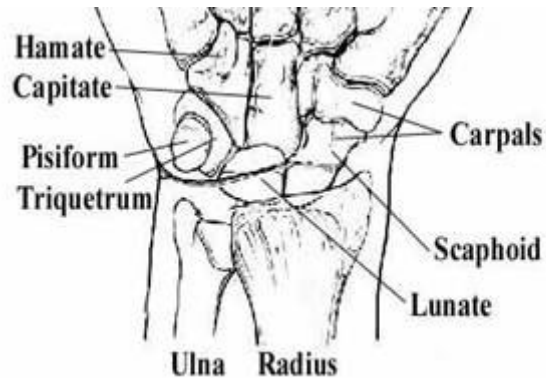
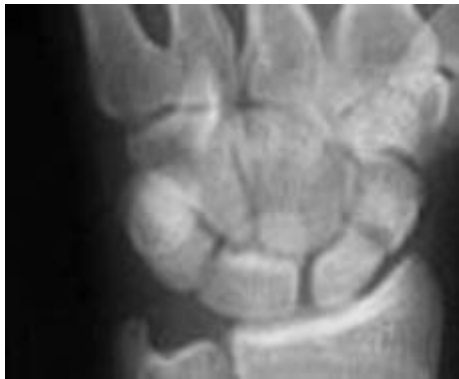

# Scaphoid Fractures

Richard A. Bernstein, MD  
The Orthopaedic Group, LLC



**Left:** an x-ray of the wrist showing a scaphoid fracture. **Right:** diagram of the wrist showing the position of the scaphoid.

## **Fractures of the scaphoid, a bone in your wrist, are not to be taken lightly.**

This is the only bone of the body that I know of that has an entire book written about how hard it is to diagnose and treat scaphoid fractures, and what to do when a fracture does not heal! Most of the time, a broken bone is obvious. The area around the break may be painful, swollen or deformed. But sometimes a bone can break without your realizing it. That's can happen to the scaphoid (pronounced "skaf'-oyd"). Some doctors call this bone the "navicular", but this is an older, out of favor term. Many people with a fractured scaphoid think they have a sprained wrist instead of a broken bone because there is no obvious deformity and very little swelling. If you've fallen and think you've sprained your wrist, call Dr. Bernstein for an appointment as soon as possible. Rest your wrist until you get seen.

The scaphoid bone is located on the thumb side of your wrist, close to the lower arm bones (see the diagram and x-ray at the top of the page). It is shaped like a cashew, which makes it hard to visualize on the x-ray.

The reason scaphoid fractures have a hard time healing is due to the anatomy of the blood supply to the bone. The blood supply is what keeps the bone alive and allows it to heal. Most of the bone is covered with cartilage, the smooth shiny material that forms the joints and allows the bones to move. Blood vessels cannot enter through the cartilage; they enter only through the bone. Since the scaphoid is mostly covered in cartilage, there is a limited area for the arteries to enter the bone. In the scaphoid, the blood supply to the bone enters from the distal end, that is, the end toward your fingers. This can be a problem for healing, since most fractures occur in the middle or lower portion of the bone. The blood supply to the proximal fragment, that is, the piece that is toward your elbow, may not have any blood supply. Without a blood supply, the bone cannot heal and that fragment may die.

### **Who Gets Scaphoid Fractures?**

Scaphoid fractures account for about 60 percent of all wrist (carpal) fractures. They usually occur in men between ages 20 and 40 years, and are less common in children or in older adults. The break usually occurs during a fall on the outstretched hand. It's a common injury in sports and motor vehicle accidents. The angle at which the hand hits the ground determines the injury. The following is a very rough "rule of thumb": If the wrist is bent at a 90-degree angle or greater, the scaphoid bone will break; if the angle is less than 90 degrees, the lower arm bone (radius) will break.

### **Signs and Symptoms**

- Pain and tenderness on the thumb side of the wrist.
- Motion (gripping) may be painful.
- May be some swelling on back and thumb side of wrist.
- Pain may subside, and then return as a deep, dull aching.
- Marked tenderness to pressure on the "anatomical snuffbox," (a triangular-shaped area on the side of the hand between two tendons that lead to the thumb.)

## **Diagnosis**

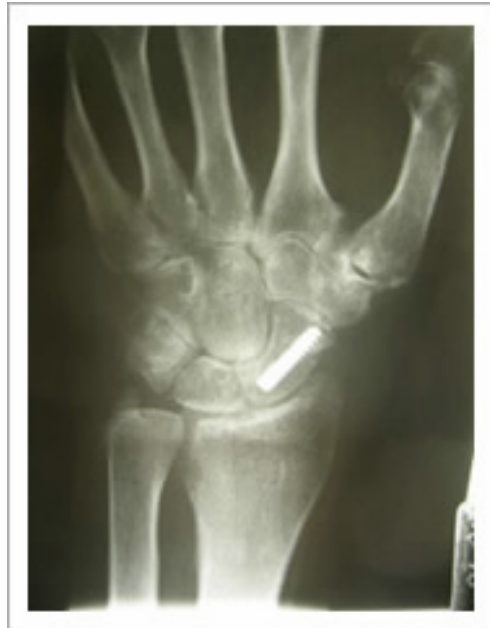The diagnosis is based on a history of trauma to the wrist (usually a fall or accident), a clinical exam that shows tenderness in the region of the scaphoid and a painful Watson test (a maneuver in which the wrist is moved back and forth, with the examiner's thumb on your scaphoid; it is just slightly painful), and x-rays that show a fracture. Sometimes, the x-ray does not show a fracture. In some cases other X-rays are needed to diagnosis the problem. Usually, with a supportive history and clinical exam, the diagnosis will be made of a probable scaphoid fracture.

## **Treatment**

Treatment is determined by the fracture site, the degree of displacement, any associated injuries, and the patient's occupation and desires.

**Cast Treatment:** Many scaphoid fractures are treated with immobilization in a cast that immobilizes the elbow, wrist, and thumb, for six weeks, and then only the wrist and thumb for an additional six weeks. Healing time, however, can range from six weeks for fractures in the top portion (toward the fingers) to six months or longer for fractures in the lower portion (toward the wrist). The cast must be checked regularly to make sure that it fits properly and prevents movement. After the cast is removed, a rehabilitation program helps restore range of motion and strength.

**Surgical Treatment:** Some fractures are displaced by 1 mm or so. These usually need surgical treatment. Scaphoid fractures that are accompanied by other injuries, usually a distal radius fracture, also need surgery. Also, with newer techniques, the risks of surgery are reasonably low that some patients choose surgery, because it usually means the patient does not need to wear a cast at all, just a splint. Over the last few years through a limited approach we can address scaphoid fractures and avoid cast immobilization. Via a small incision, I can



introduce a screw into the scaphoid and minimize the time in a cast. As with any surgery there are risks with this procedure, there is still no guarantee that the scaphoid will heal and there are risks to the wrist and tendons. The pros and cons are something that we can talk about in the office.

Not all scaphoid fractures will heal properly. The usual causes are delay in treatment or too short a time in a cast that is too short. Smoking also interferes with bone healing. However, the scaphoid is rather famous for not healing, even when everything is done properly. Surgery is usually recommended when the scaphoid fails to heal (non-union). Surgery for non-union is successful in approximately 75 percent of cases.

Sometimes a bone graft is used to promote healing. There are two types of bone grafts. One is using your own bone, often times from the radius bone of the forearm. This can bring in new bone cells to help fill the gap. The other type of bone grafting is taking a segment of bone from the radius and moving it to the scaphoid attached to a microscopic blood vessel. There are certain times to do one or the other that we can discuss in the office.

Scaphoid fractures often take a long time to heal. Any delay in getting treatment increases the risk of poor healing and the probability of more problems later. An untreated scaphoid fracture can lead to severe arthritis and eventually require surgery to fuse or replace the joint.

Copyright © 2010, TOG All rights reserved.

Revised 4/1/11